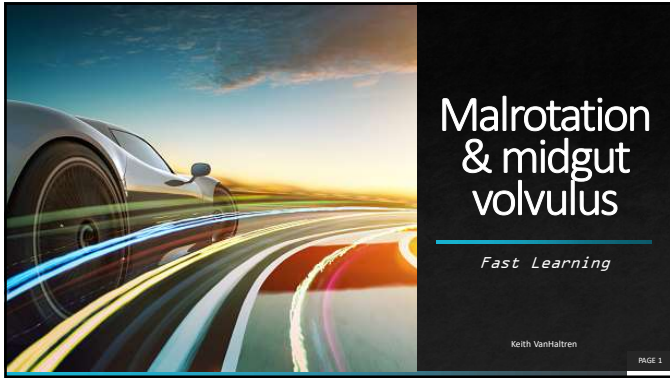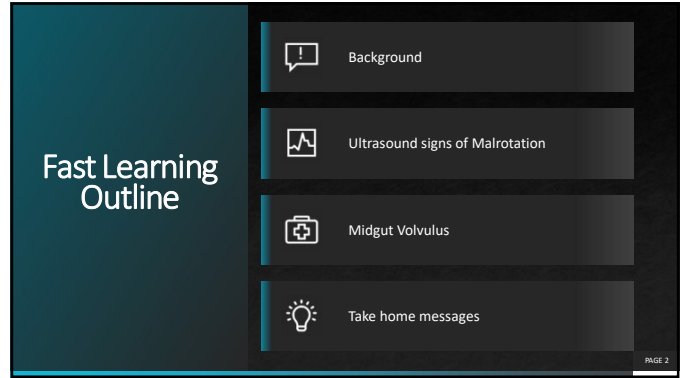
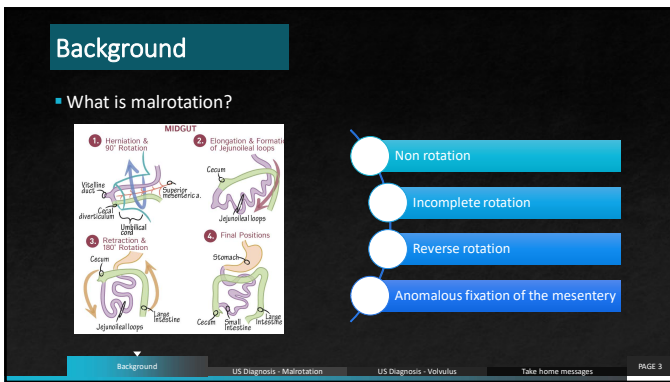




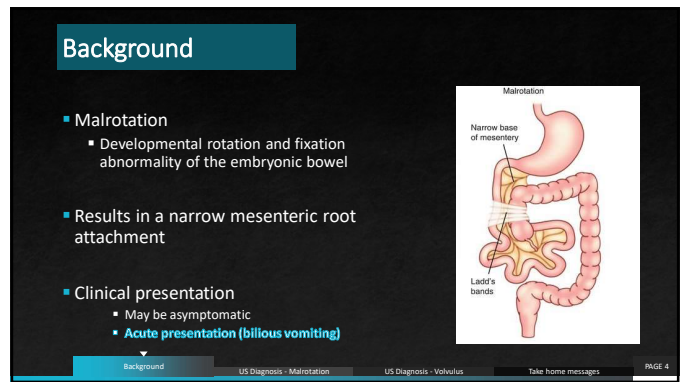
1



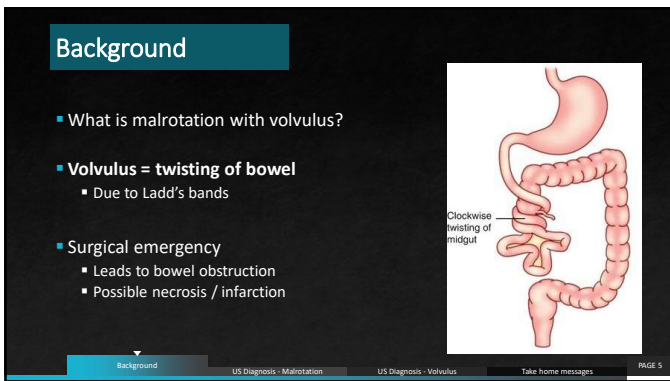
2



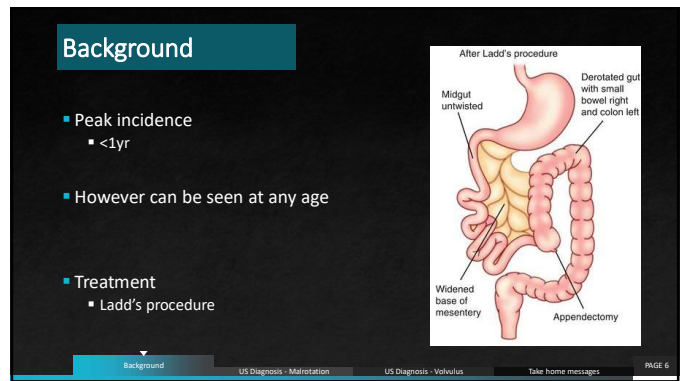
3



4



5



6

Ultrasound Diagnosis

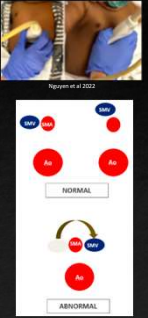
Malrotation → Malrotation with volvulus

Background US Diagnosis - Malrotation US Diagnosis - Volvulus Take home messages PAGE 7

7

Ultrasound Diagnosis

- SMA / SMV orientation
 - Small curvilinear transducer ideal
 - Start in transverse from xiphoid process
 - Scan inferiorly
 - Normal: SMV to the right of the SMA

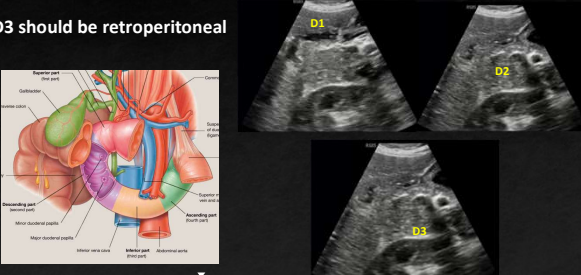


Background US Diagnosis - Malrotation US Diagnosis - Volvulus Take home messages PAGE 8

8

Ultrasound Diagnosis

- D3 should be retroperitoneal

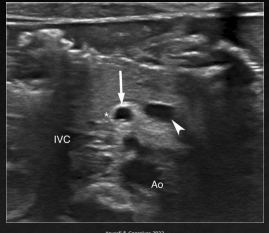


Background US Diagnosis - Malrotation US Diagnosis - Volvulus Take home messages PAGE 9

9

Ultrasound Diagnosis

- Hypoplastic uncinate process
 - Does not extend to SMV level

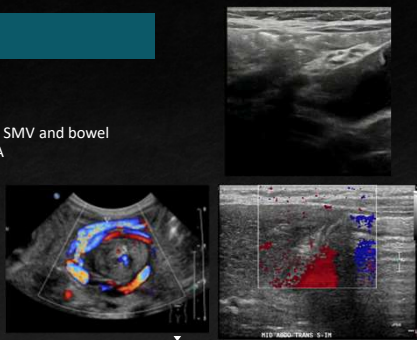


Background US Diagnosis - Malrotation US Diagnosis - Volvulus Take home messages PAGE 10

10

Midgut volvulus

- 'Whirlpool' sign
 - Clockwise swirl of the SMV and bowel loops around the SMA



Background US Diagnosis - Malrotation US Diagnosis - Volvulus Take home messages PAGE 11

11

Fast Learning Summary

Take home messages:

- Bilious vomiting should trigger you to assess for malrotation/volvulus
- The 'whirlpool' sign is a classic US appearance of volvulus
- The orientation of the SMA/SMV as well as D3 path are useful markers for malrotation

Background US Diagnosis - Malrotation US Diagnosis - Volvulus Take home messages PAGE 12

12